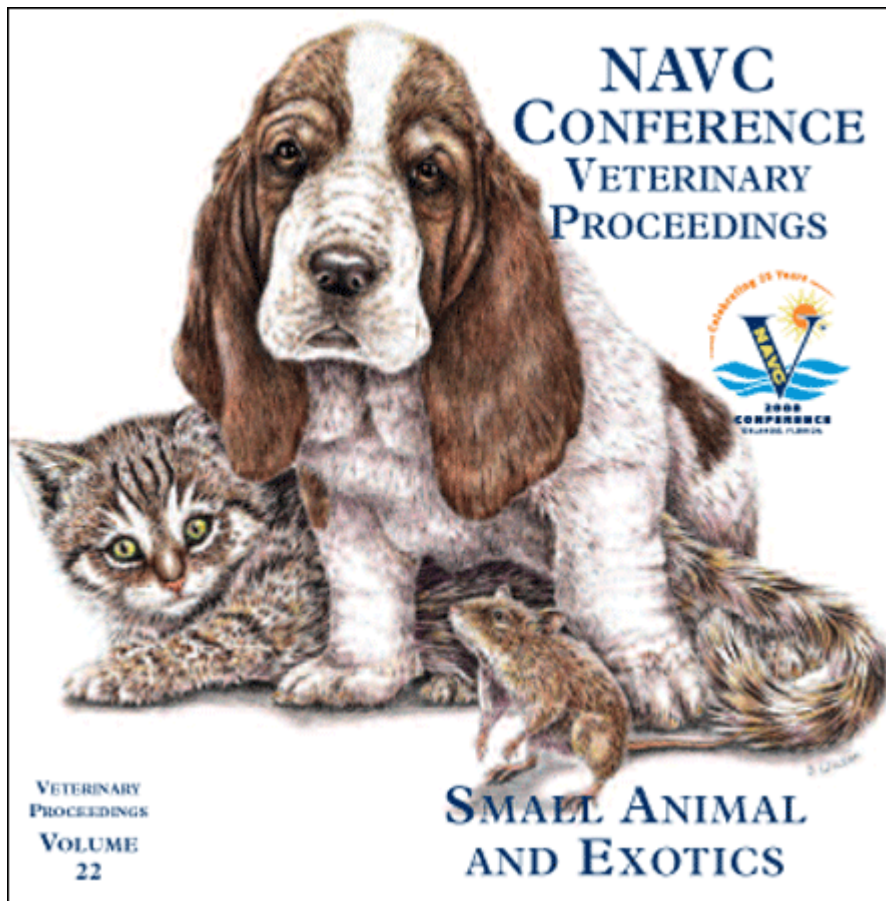


Proceeding of the NAVC
North American Veterinary Conference
Jan. 19-23, 2008, Orlando, Florida



www.tnavc.org

HALF-BODY RADIOTHERAPY FOR THE TREATMENT OF CANINE LYMPHOMA

Glenna E. Mauldin, DVM, MS
Diplomate ACVIM (Oncology) & ACVN
Cancer Centre for Animals
Western Veterinary Specialist Centre
Calgary, Alberta, Canada

Lymphoma is a commonly and successfully treated tumor in dogs. Chemotherapy is recommended in almost all cases, for two reasons. First, canine lymphoma is a systemic disease, so chemotherapy is the only way to address the animal's disease in its entirety. Second, chemotherapy is a highly effective treatment for lymphoma. CHOP-based protocols incorporating cyclophosphamide, doxorubicin, vincristine, and prednisone are the current gold standard, and complete remissions are achieved in 80% to 90% of dogs. Reported median remission durations range from 7 to 9 months, with overall median survival times in the range of 12 to 14 months.

Numerous attempts have been made to improve survival in dogs with lymphoma by making changes to the CHOP protocols in common use. Most of these have involved increasing the intensity of therapy: based on chemotherapy theory, improved responses should result if the tumor is treated more aggressively. Investigators have increased drug doses, administered drugs more frequently or even given drugs concurrently instead of sequentially. Unfortunately, the result has been unacceptable treatment-related toxicity: gastrointestinal side effects, sepsis, and more treatment-related deaths. Many owners and veterinarians are unwilling to accept such significant toxicity because quality of life, rather than quantity, is the primary concern.

New strategies are needed to improve response to therapy in dogs with lymphoma. One alternative that is currently receiving attention is multimodality therapy with both chemotherapy and radiotherapy. There are several potential advantages to this approach. Malignant lymphocytes are highly sensitive to radiation and undergo apoptosis after exposure to relatively small doses. In addition, chemotherapy and radiotherapy work by different mechanisms so radiation may offer a way to address chemotherapy resistant disease. This is a critical point, because even though canine lymphoma is a chemotherapy responsive disease, it is not a curable. Virtually all dogs eventually fail because drug-resistant disease persists subclinically and leads to relapse, and the ability to overcome chemotherapy resistance would be a tremendous advance. Finally, the addition of radiotherapy could shorten the chemotherapy protocols currently used to treat canine lymphoma. This might have multiple positive effects, including slower development of chemotherapy resistance due to decreased tumor cell drug exposure; decreased

cumulative chemotherapy toxicity; and, decreased cost and increased convenience for the pet owner.

These considerations lead several centers to incorporate radiotherapy into CHOP-based protocols for canine lymphoma. Sequential cranial and caudal half-body treatments were used to simulate a systemic treatment, since delivery of the full whole body dose would have fatal complications. Early reports were encouraging: at one institution, almost a third of dogs that received half-body radiotherapy were in remission and off therapy after two years. Several years later, results of the largest study published so far were somewhat less positive. Although the combination therapy was well tolerated, remission duration in dogs receiving half-body radiotherapy was only modestly improved at a median of 10 months. The authors of this study hypothesized that longer remissions were not achieved because the radiation dose was too low, because malignant lymphocytes survived by moving between body halves between treatments, or perhaps because some chemotherapy resistant lymphocytes were also radioresistant. However, they felt that more work looking at protocols combining chemotherapy and radiation was warranted. Unfortunately, data from these studies are now becoming available and despite initial reports they suggest that half-body radiotherapy provides little benefit compared to chemotherapy alone. Preliminary results from one study showed that dogs receiving half-body radiotherapy and chemotherapy had a median remission duration of only 7 months. In a study conducted by the author, dogs receiving half-body radiotherapy had more gastrointestinal and hematologic toxicity, and more treatment delays. Use of this protocol has been discontinued.

After evaluation of available data it is difficult to recommend routine incorporation of half-body radiotherapy into CHOP-based protocols for canine lymphoma. Even though the theory and initial reports suggested a benefit, when the protocol was actually put into practice this benefit disappeared. This shows the importance of conducting carefully designed studies to fully evaluate new therapies before they are widely adopted. Additional work may identify a subset of dogs for whom half-body radiotherapy provides an advantage, but at the present time it appears that CHOP-based chemotherapy alone should remain the standard of care for canine lymphoma.

REFERENCES

1. Rassnick KM, McEntee MC, Erb HN, et al. Half-body radiation therapy versus chemotherapy consolidation following induction chemotherapy for treatment of canine lymphoma. *Vet Cancer Soc Proc.* 2006; 26:40.
2. Williams LE, Johnson JL, Hauck M, et al. Chemotherapy followed by half-body radiation therapy for canine lymphoma. *J Vet Intern Med.* 2004; 18:703-709.