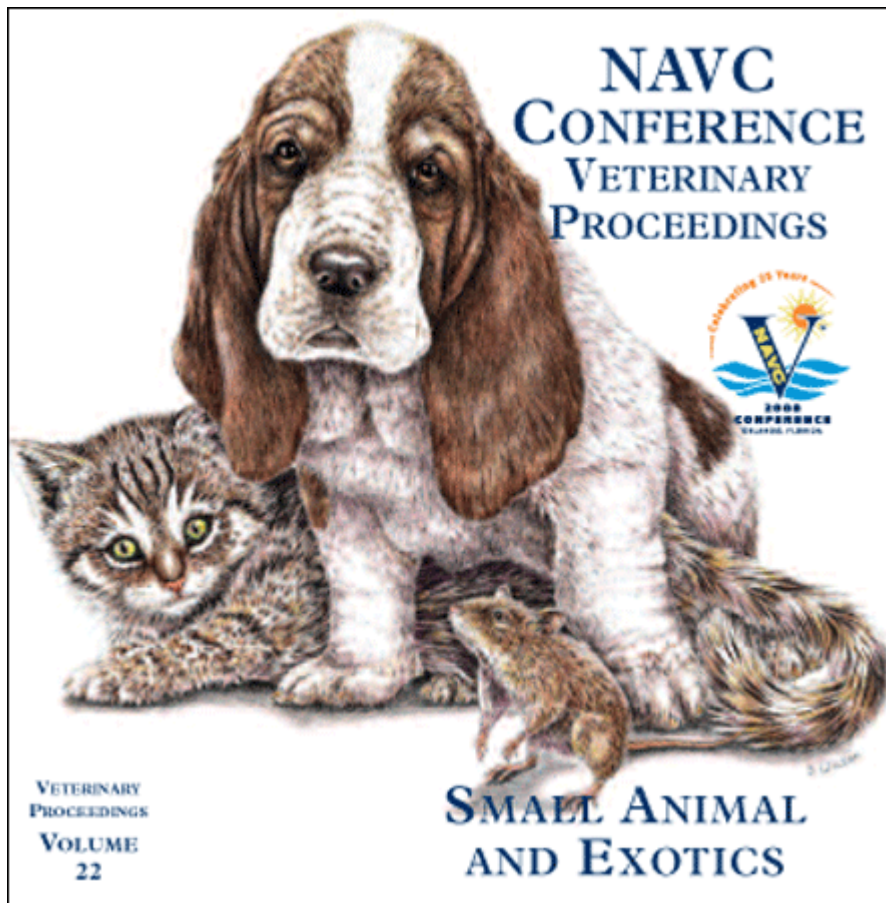


Proceeding of the NAVC
North American Veterinary Conference
Jan. 19-23, 2008, Orlando, Florida



www.tnavc.org

EXTRASKELETAL TUMORS OF BONE

Wallace B. Morrison, DVM, MS, Diplomate ACVIM
School of Veterinary Medicine
Purdue University, West Lafayette, IN

Bone in extraskeletal sites may be malignant (osteosarcoma) or benign (heterotrophic or ectopic bone formation; calcinosis circumscripta). Either may present as a boney mass associated with a soft tissue structure. Extraskeletal osteosarcoma clinically is very aggressive and survival is typically short, while benign mineralization has a much more favorable outcome.

Osteosarcoma in extraskeletal locations is rare in the dog. These tumors are bone-producing neoplasms of mesenchymal origin that lack any association with bone or periosteum. Extraskeletal osteosarcomas have been reported in cutaneous, mammary gland, muscle, gastrointestinal (GI) tract, spleen liver, thyroid gland, adrenal gland, urinary tract, reproductive, ocular, meningeal, and salivary gland tissues. Pathologists will typically use immunohistochemical techniques to further characterize tumor specimens and they often stain positive for vimentin confirming a mesenchymal origin.

The presumed pathogenesis for these unusual tumors is that they arise from resident populations of undifferentiated mesenchymal cells with osteogenic potential that are known as *inducible osteogenic precursor cells* (IOPCs). The IOPCs are different from committed or *determined osteogenic precursor cells* (DOPCs) of bone marrow origin. Both precursor cell types have multi-potentiality and possess the capacity to establish all marrow lines. The IOPCs are distinguished from DOPCs partly on initial dependency and continued persistence of appropriate microenvironment in the tissue. The microenvironment of cytokines (transforming growth factors $\beta 1$ and $\beta 2$), bone morphogenic proteins (BMP1, BMP2, and BMP3), BMP regulator proteins, and matrix proteins influence the continued activity and extent of bone formation. Transforming growth factors and related bone morphogenic proteins are especially important in inducing bone formation and stimulating differentiation of primitive mesenchymal cells into bone forming tissue.

A similar conceptual explanation may apply to extraskeletal osteosarcomas of cats such as vaccine-associated osteosarcomas and feline trauma-induced osteosarcoma of the lens. Both of these tumors develop in an environment characterized by chronic inflammation. Malignant transformation in these tumors is believed to be mediated by the favorable environment provided by the persistent activity of a number of inflammatory cytokines and growth factors that perpetuate metaplastic tissue formation and ultimately sarcoma formation.

Ectopic soft tissue mineralization that mimics bone is described by many synonyms in the literature including tumoral calcinosis, calcinosis cutis, tumoral lipocalcinosis, canine gout, hip stone, and calcinosis circumscripta among others. This syndrome has been reported in dogs and cats and other domestic and wild species of animals. Mineralization of soft tissues is generally classified into three types according to the underlying factors: dystrophic, metastatic, idiopathic, and iatrogenic calcinosis. Dystrophic mineralization occurs in patients with normal serum calcium and phosphate concentrations and the calcification is localized to specific areas of tissue damage. The primary lesion may result from trauma, inflammation, infection, necrosis, or neoplasia. Ectopic mineralization following severe inflammation have been reported with foreign body reactions, otitis externa, interdigital pyoderma, neoplasia, demodicosis, and similar conditions. Metastatic mineralization occurs in a clinical setting of hypercalcemia and/or hyperphosphatemia such as may be seen with chronic renal failure or vitamin D toxicosis. Idiopathic mineralization occurs in the absence of known tissue injury or metabolic abnormality. Iatrogenic mineralization typically arises secondary to a treatment or surgical procedure with calcification occurring at the site of invasion. One large retrospective study of ectopic soft tissue calcification found that repetitive trauma and injury can play a role in inducing this syndrome in apparently normal dogs.

REFERENCES

1. Tafti AK, Hanna P, Bourque AC. Calcinosis circumscripta in the dog: a retrospective pathological study. *J Vet Med.* 2005; 52:13-17.
2. Langenbach A, Anderson MA, Dambach DM, et al. Extraskeletal osteosarcoma in dogs: a retrospective study of 169 cases (1986-1996). *J Am Anim Hosp Assoc.* 1998; 34:113-120.
3. Ringenberg MA, Neitzel LE, Zachary JF. Meningeal osteosarcoma in a dog. *Vet Pathol.* 2000; 37:653-655.
4. Thomsen BV, Myers RK. Extraskeletal osteosarcoma in the mandibular salivary gland of a dog. *Vet Pathol.* 1999; 36:71-73.
5. Spugnini EP, Ruslander D, Bartolazzi A. Extraskeletal osteosarcoma in a cat. *J Am Vet Med Assoc.* 2001; 219:60-62.
6. Dhaliwal RS, Johnson TO, Kitchell BE. Primary extraskeletal hepatic osteosarcoma in a cat. *J Am Vet Med Assoc.* 2003;222:340-342
7. Kuntz CA, Dernell WS, Powers BE, et al. Extraskeletal osteosarcomas in dogs: 14 cases. *J Am Anim Hosp Assoc.* 1998; 34:26-30.