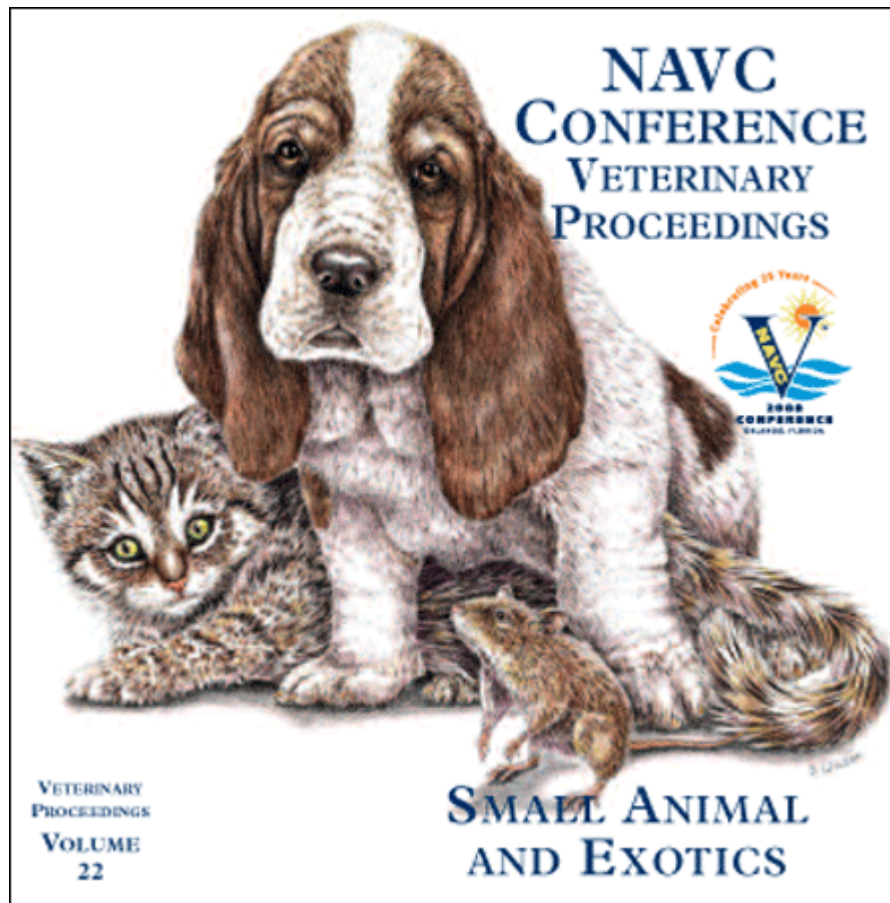


Proceeding of the NAVC  
North American Veterinary Conference  
Jan. 19-23, 2008, Orlando, Florida



[www.tnavc.org](http://www.tnavc.org)

## AMPUTATION OR LIMB SALVAGE FOR OSTEOSARCOMA: WHAT'S BEST?

Nicole Ehrhart, VMD, MS, Diplomate ACVS  
Animal Cancer Center  
Colorado State University, Fort Collins, CO

### AMPUTATION

For most dogs and cats, amputation is, by far, the easiest, least complicated, and most cost effective treatment to remove the primary tumor in cases of osteosarcoma. Amputation is a surgical technique most veterinarians are familiar with and it requires no specialized surgical equipment other than the standard surgical pack. For primary tumors involving the forelimb, a forequarter amputation is recommended. This method results in superior cosmetic results for most dogs. In addition, if the primary tumor is in the proximal humerus, forequarter amputation will provide for clean surgical margins, whereas disarticulation at the scapulo-humeral joint will result in residual local disease left in the patient. For hindlimb tumors, a coxofemoral disarticulation is preferred over a mid-femur osteotomy especially in cases where the tumor is in the distal femur. Removing the entire femur ameliorates the risk that the tumor has spread proximally within the marrow cavity where it is not apparent radiographically. In cases in which the tumor is located in the proximal femur (femoral neck), an acetabulectomy (without opening the coxofemoral joint) is recommended. This technique is similar to a partial hemipelvectomy where the entire coxofemoral joint including the acetabulum and associated joint capsule is removed *en bloc* with the limb. In cases of proximal femur osteosarcoma, coxofemoral disarticulation has resulted in a high rate of local recurrence.

Contrary to popular myth, large and giant breed dogs do quite well with amputation, even if there is existing degenerative joint disease. We very commonly perform amputations on large and giant breed dogs, as this is the patient population that is most likely to have osteosarcoma. Most owners are more comfortable with limb amputation in their pet if they understand that while larger dogs may take more time to adjust, they typically enjoy an excellent quality of life. When one compares the risk of long-term complications between limb-sparing surgery and amputation, amputation clearly comes out the winner. So, in comparison, when complications related to chemotherapy are set aside, dogs with amputations spend less time at the veterinarian's office and enjoy far fewer surgical complications than dogs undergoing limb-sparing surgery.

### LIMB-SPARING TECHNIQUES

Limb sparing (limb salvage) is one of several alternatives to amputation. There are several limb-sparing techniques available. Nearly all (except intraoperative radiation) require that the tumor is located in the distal radius or mid-diaphyseal region within a long bone. Other sites have not been successfully salvaged and may be better candidates for palliative treatments if amputation is not possible. Other candidacy

requirements for limb salvage are that there is no metastatic disease, no pathologic fracture, and no existing co-morbidities that would preclude the dog from living out the expected median survival time (eg, dilated cardiomyopathy [DCM], severe unregulated diabetes). It is important to inform the client that limb salvage procedures are nearly always more complicated than amputation and are considerably more expensive. At CSU, most techniques cost about \$7000 for the surgery and immediate postoperative care. The cost of chemotherapy and follow-up visits with radiographs are additional.

### Traditional Limb-Sparing Surgery Using Cortical Allografts

Traditional limb-sparing surgery involves a marginal resection of the involved tumor bone and replacement of the defect with a cortical allograft and stabilization with internal fixation. Arthrodesis of the adjacent joint is usually necessary, although in cases where the tumor is located in the mid diaphysis of a long bone, intercalary grafting is possible with excellent results. In our experience, distal radius and ulna sites result in the best function following limb spare. Arthrodesis of the carpus is well tolerated by dogs of most any size. With arthrodesis of the shoulder, stifle or tarsus, function ranges from very poor to good and the complication rate is considerably higher than distal radius or ulna sites, especially in larger dogs. For these reasons, we generally recommend amputation (for amputation candidates) for osteosarcoma in sites other than distal radius or ulna. Limb sparing should be questioned for dogs presented with metastatic disease due to the cost and commitment required for the procedure in light of a short-term survival outlook. Limb-sparing candidates are those that show radiographic tumor involvement of 50% or less of the involved bone. Involvement of both distal radius and ulna will not preclude a patient from limb sparing, but the complication rate can increase. In these cases a radial allograft is used, but the ulna is not grafted. Ulna lesions are generally treated by ulnectomy without allograft placement since the radius is the primary weight-bearing bone. Pathologic fractures increase the chances for soft tissue contamination with tumor cells locally and amputation should be considered.

For large tumors, especially those with large soft tissue components, preoperative downstaging of local disease can improve the success of the procedure as well as the ease of resection. Our work has demonstrated that approximately 30 Gy of radiation (traditionally in 10 3 Gy fractions) combined with cisplatin as a radiation sensitizer will result in 80% or better necrosis of the tumor. This degree of necrosis has been shown to significantly reduce local tumor recurrence. Higher radiation doses are required to obtain the same degree of necrosis if radiation is used alone; increasing the occurrence of radiation-related complications.

Complications following limb sparing include tumor recurrence, infection, and implant failure. Proper case selection is paramount. MRI of the affected leg is often helpful to determine the proximal extent of marrow

involvement. These results are combined with the bone scan results and radiographs help determine the level of resection to ensure that no disease is left behind. Advanced imaging is very helpful; however, limb sparing requires that the plane of dissection is close to the tumor to ensure "sparing" of as much normal tissue as possible. Thus, local recurrence occurs more frequently with limb-salvage procedures than with amputation where large normal tissue margins are obtained. Local tumor recurrence can often be treated with a re-sparing procedure, especially if it occurs in the adjacent bone. As would be expected, success rates drop with successive local recurrence and salvage procedures. If further salvage is not feasible, amputation can be re-considered.

The most frequent complication seen (outside of osteosarcoma disease) following limb sparing is infection. An infection rate approaching 50% is common. This is due to multiple factors including extensive surgical field, large resection with compromise of arterial, venous and lymphatic flow, local and/or systemic chemotherapy with or without radiation, large allograft and metallic implants and lack of soft tissue covering (especially distal radius and ulna). Infection rate is high despite intraoperative and long-term postoperative antibiotic therapy. Many infections can be controlled with appropriate antibiotic therapy. A small percentage cannot be controlled and end in amputation. We have been able to improve our treatment success of severe infections with the surgical implantation of aminoglycoside antibiotic-impregnated polymethyl-methacrylate beads, presumably due to overcoming bacterial resistance.

As a result of the high infection rate, several new alternatives to allograft limb salvage have been explored. These procedures are briefly described below.

### **Bone Transport Osteogenesis**

This technique utilizes circular external fixators to perform a procedure known as bone transport limb salvage. This method of limb salvage involves resection of the bone tumor followed by slow transportation of a nearby segment of bone into the defect. Using the principles of Ilizarov (the Russian physician credited with discovery of bone transport osteogenesis), the bone segment is slowly transported into the defect while new, autogenous bone forms in the trailing distraction pathway. The major advantage to bone transport limb salvage is that the new bone formed by this method is autologous tissue and has an excellent blood supply. Thus the newly bone is highly resistant to infection. Other advantages are the lack of a need for bone banking, donor animals, or internal fixation. In addition, animals are fully weight bearing during the transport process and after the initial surgery; the transport can be performed by the client at home. Its disadvantages are that it is relatively complicated to perform and requires that the patient wear an external fixator for a length of time sufficient to create the new bone. Despite some limitations, initial long-term results are very encouraging

and current research is aimed at improving frame design and decreasing time of transport.

### **Intraoperative Radiation**

A second technique (affectionately known as the "flip-n-nuke" technique) involves extremely high single doses of irradiation given to the affected bone at the time of surgery. This technique is aimed at killing all cells (normal and malignant) in the tumorous bone region while protecting normal soft tissues. The irradiated bone and tumor is reinserted and serves to perfectly reconstruct the defect. This technique involves osteotomy above or below the affected site and removal of soft tissues from the tumor bone. The neurovascular bundle is held away from the affected bone and the tumor is pivoted from the site on the intact joint tissues. A single dose of 70 Gy radiation is then directed to the tumor. The radiated bone is then anatomically replaced and fixed back into position using either an interlocking nail system or dynamic compression plating. The advantage to this technique is in the potential sparing of joint function and the potential use in non-distal radius sites. To date, two proximal humeral sites, one distal humeral site, one distal femur and one distal tibia have been treated. All patients have had at least good initial function. Long-term results have been less encouraging, however. Four patients have had to have implant revisions within 5 months of initial surgery, including one amputation. Local tumor recurrence has occurred in two patients and infection in two patients. Follow-up on this subset is relatively short and further evaluation as well as technique modification is indicated before this technique can be recommended routinely.

### **Ulna Autograft Technique**

This limb-sparing method involves the use of the ipsilateral ulna as an autograft. Two techniques have been employed to use a vascularized ulna graft to reconstruct the distal radius defect. The vascular supply of the distal ulna graft is based upon the musculoperiosteal cuff formed by the pronator quadratus, abductor pollicis longus and ulnar head of the deep digital flexor muscles. The vascular supply is the caudal interosseous artery and vein. In one method, the ulna is pivoted on an intact vascular pedicle. In the other method, direct microvascular anastomosis is performed between the caudal interosseous artery and vein and the radial artery and vein. The microvascular anastomosis method is useful in cases where the tumor has invaded the distal aspect of the ipsilateral ulna, because portions of the proximal ulnar diaphysis may be used or, in some cases, the contralateral ulna.

### **Metal Endoprostheses**

This limb-sparing method utilized a metal endoprosthesis in place of the traditional allograft. Initially, this method was developed in an attempt to decrease infection rates. While, early data suggests that there is only a modest, if any, decrease in infection, this technique is technically very simple and may allow limb-sparing procedures to become more widely available. In

Small Animal – Oncology

---

addition, endoprosthesis reconstructions may eventually be able to be combined with total arthroplasty techniques to allow better overall function and provide limb-sparing options for anatomic locations other than the distal radius to be considered.

**OTHER OPTIONS**

When limb sparing is not feasible there are additional alternatives other than amputation to consider. Palliative radiation therapy has excellent success at relieving pain. The protocol involves 3 to 4 treatments of radiation with various intervals between successive dosing and is fairly

inexpensive compared with other treatments. Approximately 85% to 90% of dogs have an excellent response. Pain relief lasts for 3 to 4 months on average. We have some experience with adding chemotherapy to palliative radiation protocols. These patients have received various chemotherapy protocols including doxorubicin as a single agent, alternating doxorubicin and cisplatin (or carboplatin) and cisplatin (or carboplatin) as a single agent. We have observed survival times in the 8- to 9-month range in some animals, although these results are not consistent and prospective studies have not been performed.